

## Summary Feedback

(Combined feedback broadcasted at multiple times this week)

### **PRE-RECORDED: Basildon FRCR 2B 'A to Zee' Course 2020**

## **Session 4/38**

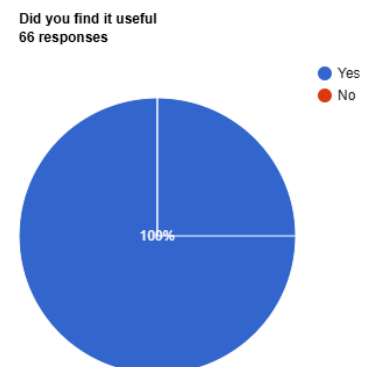
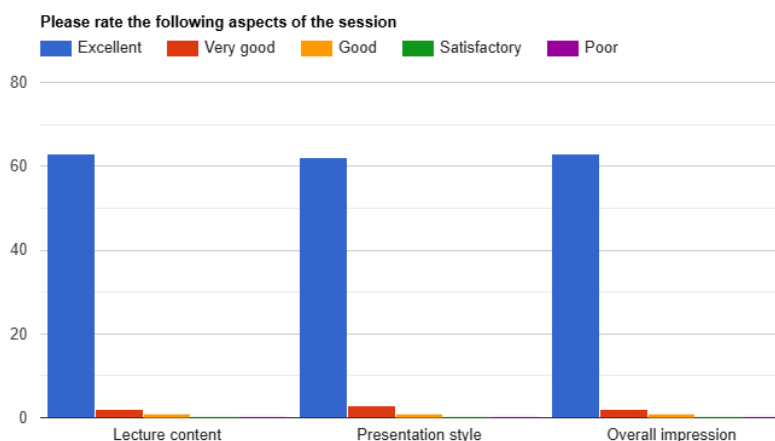
### **Chest & Cardiac Imaging For FRCR- (Part-2)**

**(12<sup>th</sup> & 13<sup>th</sup> April 2025)**

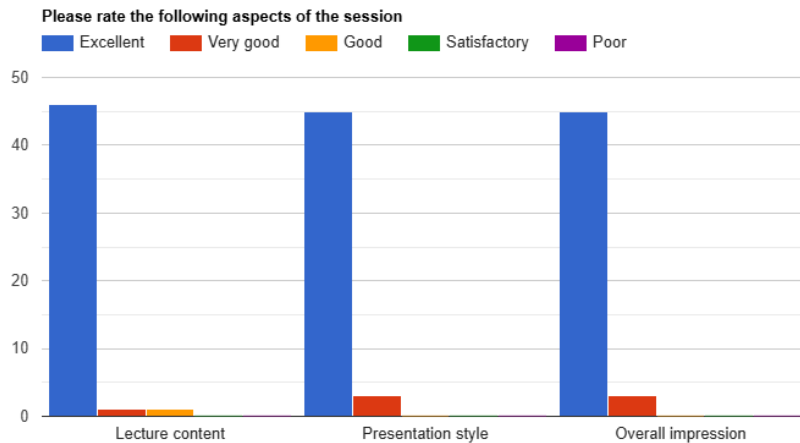
**Lecturer: Alexia Farrugia**

#### **Summary Points:**

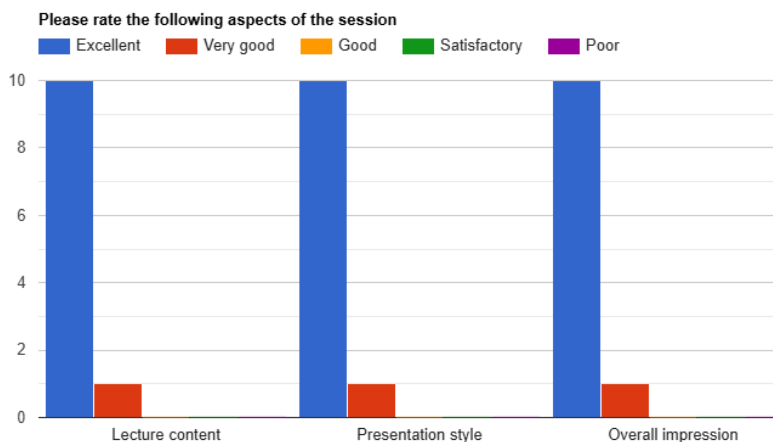
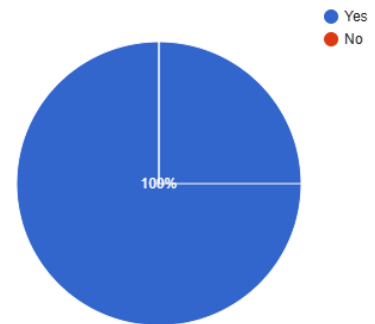
- Total Attendees: 360 from 32 Countries (Algeria, Australia, Bangladesh, China, Dominica, Egypt, Ethiopia, France, Ghana, India, Indonesia, Iraq, Jordan, Kenya, Libya, Malaysia, Netherlands, Nigeria, Norway, Oman, Pakistan, Saudi Arabia, Singapore, South Africa, Sri Lanka, Sudan, Swaziland, Türkiye, UAE, UK, Yemen, Zimbabwe).
- Total duration: 2 hours (each session broadcasted thrice during the week)
- Total feedback received from 125 participants, from three different broadcasts



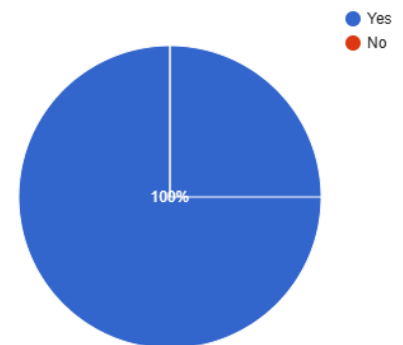
## Chest & Cardiac Imaging For FRCR- (Part-2)



Did you find it useful  
48 responses



Did you find it useful  
11 responses



## Testimonials

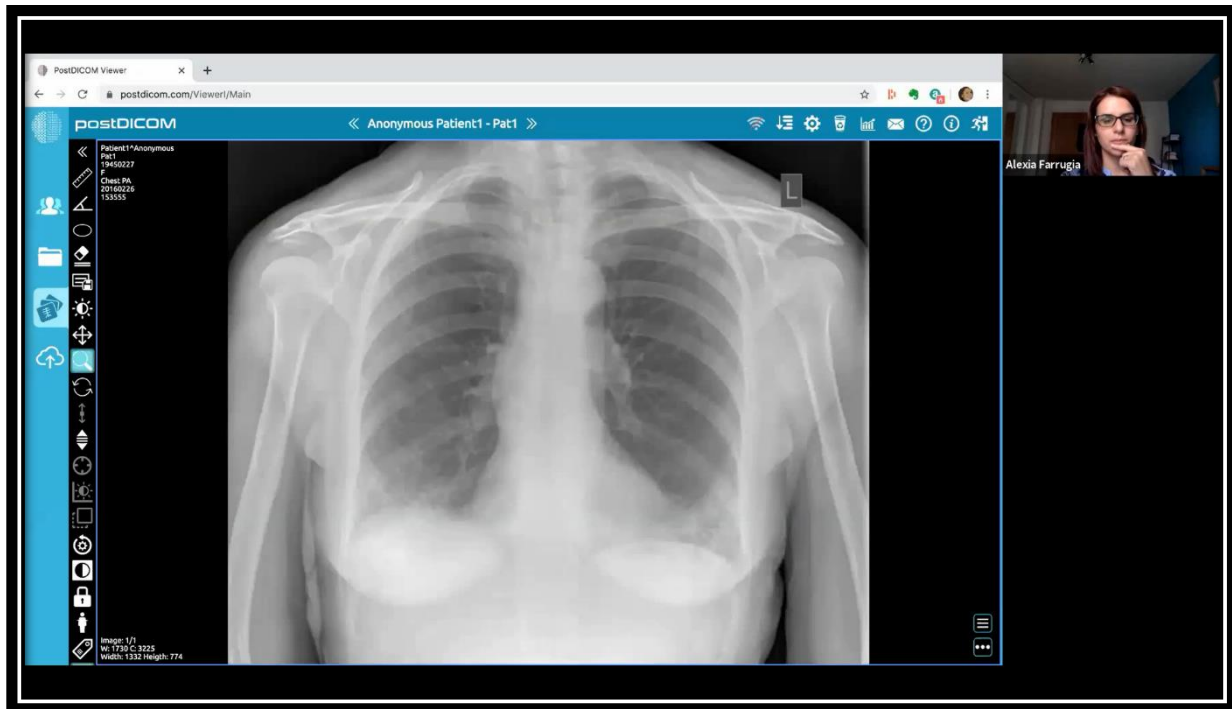
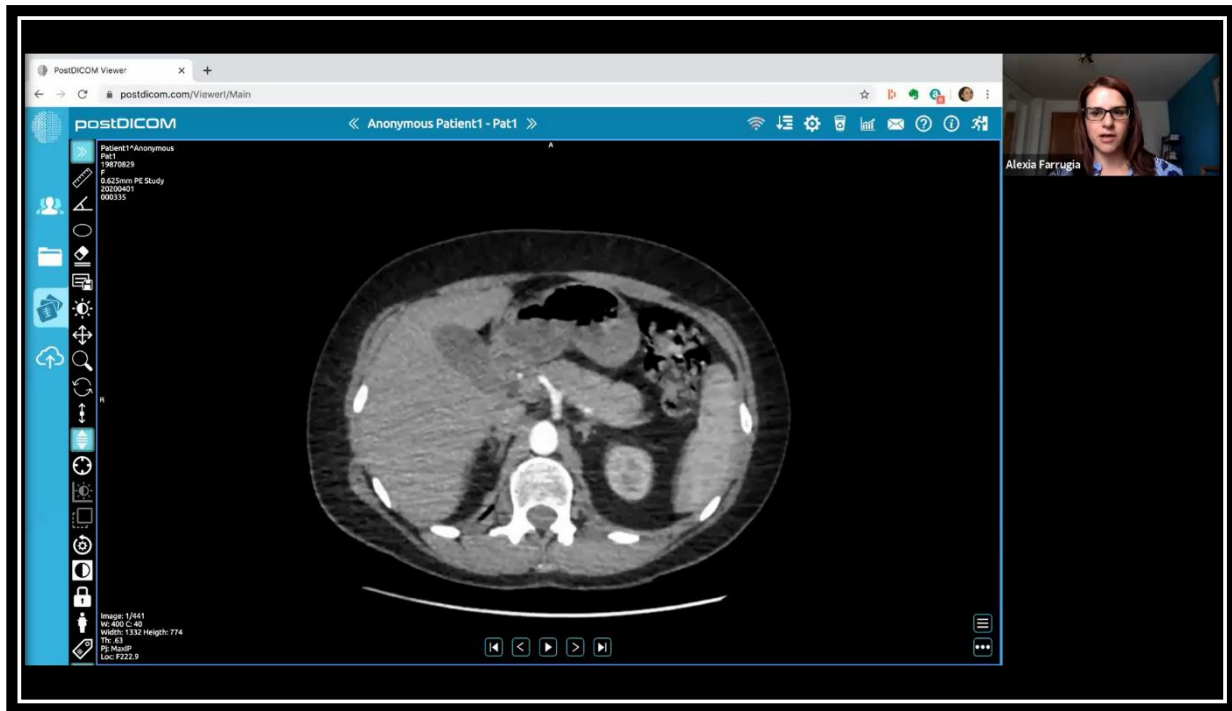
- Clear explanation of the findings and importantly, clear and concise differentials. This was clearly made by someone who understands the exam format and how to prepare (UK).
- Well done, the teaching content and slides after each case were brilliant. Overall, excellent talk. Covered all the aspects of chest radiology (Zimbabwe).
- Yet again very, very useful, diverse chest imaging cases. Thank you for sharing with us. (India).
- Informative for me. I left radiology long, long ago. So it was a good dusting exposure for me!! (Pakistan).
- Excellent case collection and consolidated review slides about the pathologies (UK).
- Well explained and great teaching and discussion on various chest and cardiac imaging delivered by Dr. Alexia! (Malaysia).
- Excellent choice of cases....best description by candidates and Dr Alexia...best session as always (Pakistan).
- Lung is the greatest field for pathology - never ending story. Always interesting cases (UK).
- Well explained and great teaching and discussion on various chest and cardiac imaging delivered by Dr Alexia! (Malaysia).
- Excellent cases selection and discussion (UAE).
- It is a great resource for chest cases review (Ethiopia).
- Very good presentation (Sri Lanka).

## Chest & Cardiac Imaging For FRCR- (Part-2)

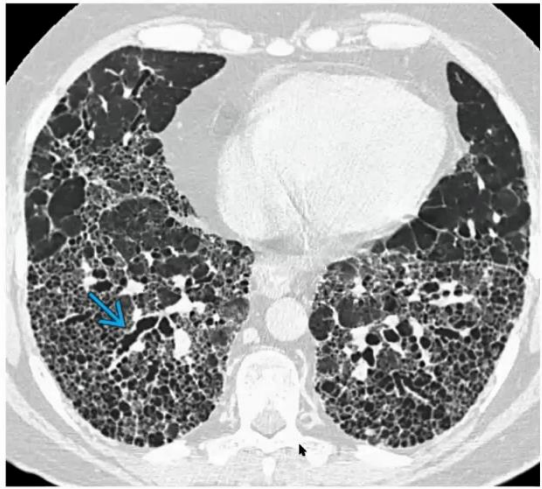
- Very educative session (Nigeria).
- Great presentation (Iraq).
- Very close to exam pattern cases (Saudi Arabia).
- I liked the variety of cases and the knowledge of the examiner (Malaysia).
- Excellent lecture by Dr. Alexia Farrugia! Brilliant cases (Pakistan).
- Good cases (South Africa).
- The variety of cases and PowerPoint presentation of the cases were amazing (Pakistan).
- Very useful (Saudi Arabia).
- Concise and superb teaching and explanation by Dr. Alexia (Malaysia).
- Excellent session with great reviews of common cardiothoracic cases (UK).
- Very good lecture (UK).
- Great lecture and beautifully presented cases (UK).
- Concise and superb teaching and explanation by Dr. Alexia (Malaysia).
- Excellent lecture (UK).
- Very useful (Iraq).
- I liked the case discussion points (Malaysia).
- I liked the approach towards cases (Pakistan).
- It's all useful (UAE).
- Exam oriented with good variety of cases (UAE).
- Great collection of cases and teaching style (Pakistan).
- Thanks for another wonderful and informative session (Pakistan).
- The discussion after each case providing differential diagnosis was very useful (UK).
- Way of explanation was superb (Pakistan).
- All the contents were very useful (UK).
- I liked the cases and how the presenters present (Malaysia).
- Excellent series of variety of cases and explanations (Pakistan).
- Great cases and explanations (UK).
- Excellent teaching (UK).
- The case discussions were very useful (Zimbabwe).
- Excellent session (Nigeria).
- Very informative (UAE).
- Great teaching (Pakistan).
- Very educative (Nigeria).
- Excellent radiology learning platform. Long Live Dr Khan and his team! (Pakistan).
- Very informative (Saudi Arabia).
- It was perfect (UAE).
- Great knowledge (Pakistan).
- It's great (Egypt).
- Good lecture (Sudan).
- It's good (Egypt).
- Great cases (Kuwait).
- I liked the type of cases (Oman).
- Detailed explanation on diagnosis and differentials given (Zimbabwe).
- The images and comparing the CXR and the CTs were very nice (UK).
- Cases are so practical (Ethiopia).
- Excellent content and delivery (UK).
- Great cases and case based teaching (Egypt).

## Chest & Cardiac Imaging For FRCR- (Part-2)

- Very, very good teaching and very good cases (Pakistan).
- It was perfect (UAE).
- Great teaching points (Zimbabwe).
- All of it was very helpful & valuable (Egypt).
- Amazing teaching style (Nigeria).
- Nice cases (Iraq).



## Chest & Cardiac Imaging For FRCR- (Part-2)



Axial CECT of the same patient shows extensive basilar predominant honeycombing with traction bronchiectasis (cyan solid arrow) and bronchiolectasis that would be reported as usual interstitial pneumonia (UIP) pattern. Honeycombing is the most specific feature of IPF on CT.

Alexia Farrugia

=====XX=====XX=====